

THE DENTAL ADVISOR

TM

"Improving Patient Care Through Research & Education"

Estelite Sigma Quick 2-year Clinical Performance

+++++

Tokuyama Dental
877.378.3548
www.tokuyama-us.com

Description

Estelite Sigma Quick is a submicron-filled, low-shrinkage composite indicated for anterior and posterior class I-V restorations. *Estelite Sigma Quick* implements RAP technology (Radical-Amplified Photopolymerization initiator technology), which offers increased working time of 90 seconds under ambient light and decreases the curing time to 10 seconds with a halogen light. *Estelite Sigma Quick* is available in both syringes and pre-loaded tips (PLTs) in shades: A1, A2, A3, A3.5, A4, B1, B2, B3, B4, C1, C2, C3, OA1, OA2, OA3, OPA2 (opalescent), BW (bleach white), WE (white enamel), and CE (clear enamel). This product received a 99% clinical rating.

Clinical Evaluation Protocol

- 1836 *Estelite Sigma Quick* restorations were placed using a wide variety of 6th- and 7th-generation bonding agents.
- 353 restorations (molars – 47%, premolars – 27%, anterior teeth – 26%) in 163 patients were available for evaluation of clinical performance up to 24 months after placement. The distribution of restorations is shown in Figure 1.
- Restorations were evaluated on a 1-5 rating scale: 1 = poor, 2 = fair, 3 = good, 4 = very good, 5 = excellent.



Consultants' Comments

- ◆ "After two years in service, these restorations continue to retain the esthetics achieved at placement."
- ◆ "This material has exhibited excellent resistance to chipping and fracture in the anterior and posterior regions over the past two years."
- ◆ "After two years of placing this material, the excellent handling, rapid cure and esthetics continue to make this my material of choice."

Distribution of Estelite Sigma Quick Restorations Recalled at 2 Year

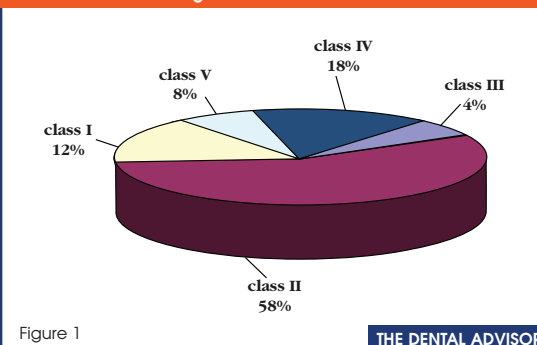


Figure 1

THE DENTAL ADVISOR

REPRINT

EDITORS

John W. Farah, D.D.S., Ph.D.
John M. Powers, Ph.D.

EDITORIAL BOARD

John A. Molinari, Ph.D.
Peter Yaman, D.D.S., M.S.
William A. Gregory, D.D.S., M.S.
Santine Anderson, D.D.S.
Sabiha S. Bunek, D.D.S.
Lori K. Brown, D.D.S.
Brent Kolb, D.D.S.
Nizar Mansour, D.D.S.
Charles I. McLaren, D.D.S., M.S.
Kathy O'Keefe, D.D.S., M.S.
Thomas Poirier, D.D.S.
William T. Stevenson, D.D.S.
Robert J. Stevenson, D.D.S.
Gytis Udrys, D.D.S.

EXECUTIVE TEAM

Sabiha S. Bunek, D.D.S.
Jackie Farah, M.A.Ed.
Annette M. Frederick
Heidi L. Graber
Jennifer Kalasz
Pari Karani, M.S.
Craig Macfarlane
John A. Molinari, Ph.D.
Tricia G. Price
Joelle Prose, M.B.S.
Nelson Williams, M.S.
Mary E. Yakas, B.A., CMC
Ron Yapp, M.S.

PUBLISHER

Dental Consultants, Inc.

Please send inquiries and address changes to: **THE DENTAL ADVISOR**
3110 West Liberty, Ann Arbor, MI 48103
Call: 800.347.1330 • 734.665.2020
Fax: 734.665.1648
E-mail: info@dentaladvisor.com
Web Site: www.dentaladvisor.com

No unauthorized duplication or reprints may be made. Inquiries concerning duplication may be directed to the publisher.

Copyright ©2011, Dental Consultants, Inc. All rights reserved. Printed in the U.S.A. (ISSN 0748-4666) by Print-Tech, Inc.

Ratings

Excellent	+++++
Very Good	++++
Good	+++

Clinical Observations

Resistance to Fracture

Estelite Sigma Quick performed very well after two years in service (Figure 2). Eleven restoration exhibited slight chipping and none requiring replacement. There were seven debonds during the two years since placement. All of the debonds were facial/buccal restorations.

Esthetics

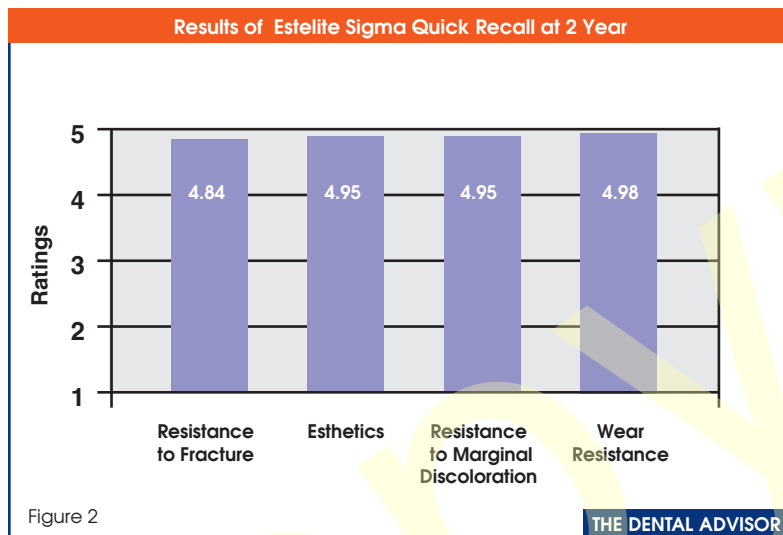
Estelite Sigma Quick exhibited very good esthetics both in the anterior and posterior regions after two years in service (Figure 2). The rapid cure time and excellent viscosity facilitated placement of the resin composite in all areas of the mouth. The excellent esthetics was a result of a variety of shade availability and the cameleon effect of the material.

Resistance to Marginal Discoloration

All of the *Estelite Sigma Quick* restorations were placed using self-etching bonding agents. Ninety-eight percent of the restorations had no marginal discoloration after two years (Figure 2).

Wear Resistance

Estelite Sigma Quick maintained excellent wear resistance both in the anterior and posterior regions after two years in service (Figure 2).



Summary

Three hundred fifty-three *Estelite Sigma Quick* restorations in 163 patients were available for recall up to two years after placement. A 2% debond rate and excellent resistance to marginal discoloration were observed when the resin composite was used with a wide variety of self-etching bonding systems. At two-year recall, the majority of restorations exhibited excellent resistance to chipping and very good esthetics. ■