

Direct aesthetic restorations: “no more temporary fillings”

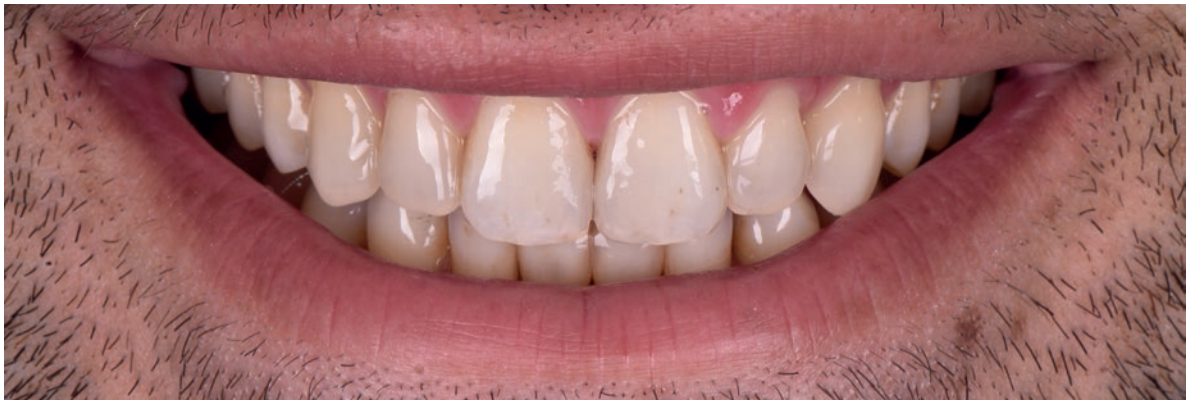
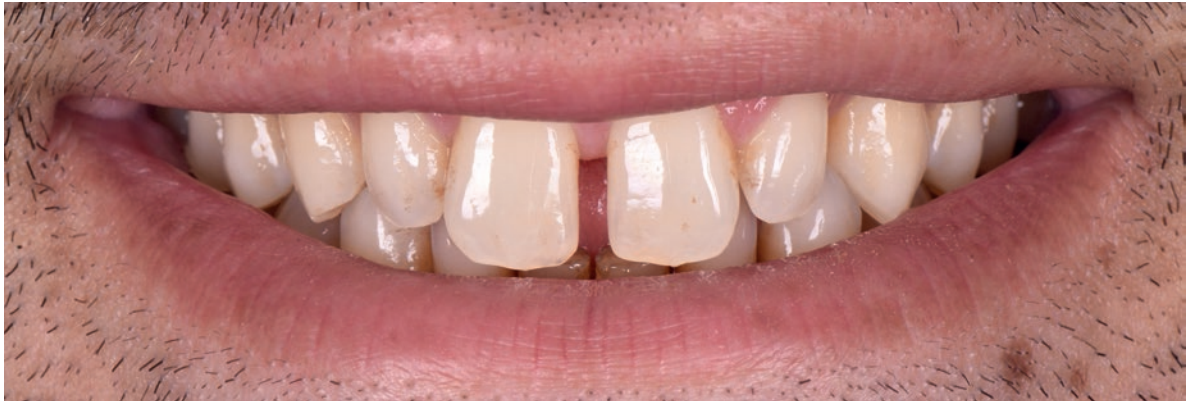
DR. BORA KORKUT

Marmara University, Dentistry Faculty
Restorative Department, Istanbul - Turkey

CASE REPORT

The developments of materials and methods in adhesive dentistry lead more aesthetic, functional and minimally invasive direct resin restorations. Single visit treatment option is one of the main advantages of these natural alike restorations when considering the treatment plan. Polychromatic or monochromatic, minimally invasive composite veneer restorations covering whole labial/buccal surface of anterior teeth, are also good treatment options compared to the rival ceramic veneer restorations. Direct composite veneers were told to have some disadvantages as instability and discoloration in the past years. However with correct indication, good isolation, successful adhesion, proper technique, detailed polishing procedures and frequent recalls, these restorations may have long-term clinical success. Formerly called ‘temporary fillings’ are called ‘direct aesthetic restorations’ now as they deserve.



BEFORE AND AFTER

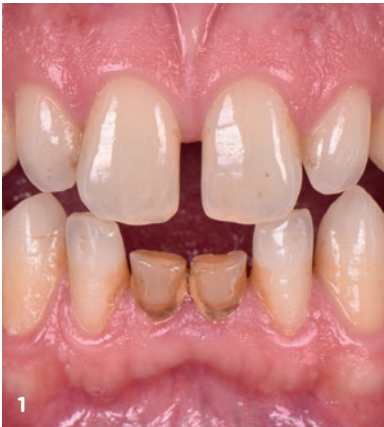

Fig. 1/2 - initial (Intraoral)

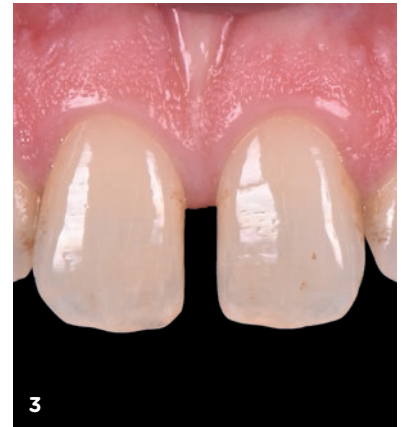
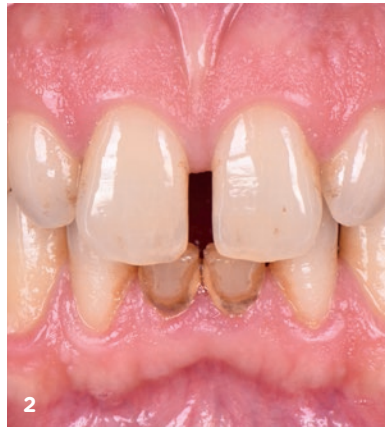
Fig. 3 - initial (Contrastor)

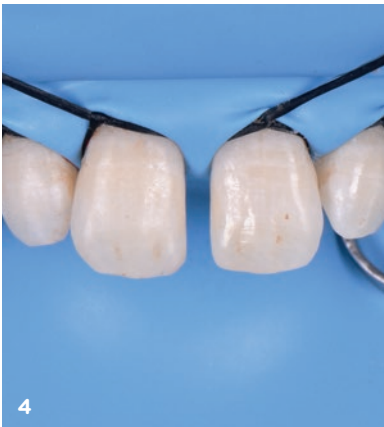

Fig. 4 - isolation

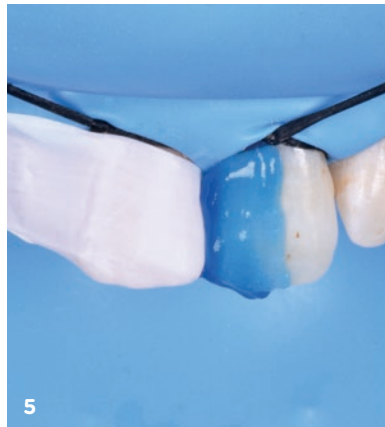


Fig. 5 - Monochrom layering

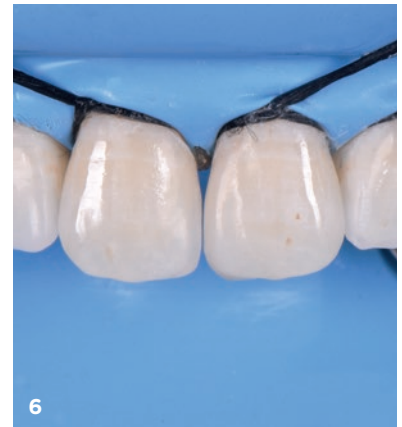

Fig. 6 - Final restorations

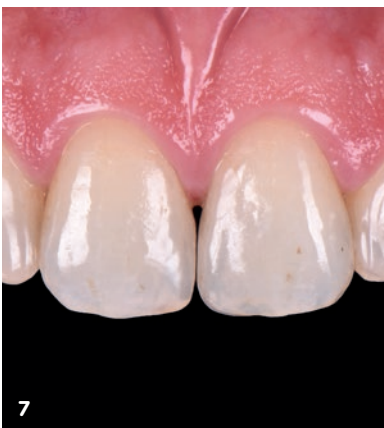

Fig. 7 - Just after the treatment

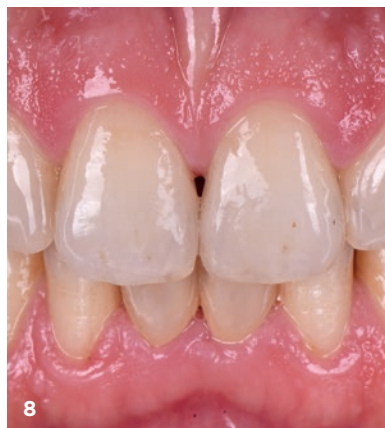

Fig. 8/9 - One week recall

Maxillary non.prep restorations were done with just OMNICHROMA
 Mandibular centrals were restored with direct veneers using OMNICHROMA BLOCKER and OMNICHROMA